

Ulnar Artery Perforator Flap for the Coverage of Electric Injury Defects at Wrist

KAMRAN KHALID, WASEEM HUMAYOUN

ABSTRACT

Aim: To determine the reliability of ulnar artery perforator flap for the coverage of electric injury defects at wrist.

Methods: This descriptive study was conducted at Plastic Surgery Department Jinnah Hospital, Lahore, from October, 2013 to August, 2015. All male and female patients between 5 -65 years of age, having post electric injury wounds or unstable scar exclusively on volar surface of wrist were included in this study. The patients with damaged proximal ulnar artery or having peripheral vascular disease were excluded from the study.

Results: There were 15(79%) were male and 4(21%) were female with soft tissue defects or unstable scar over the wrist. Partial flap necrosis without dehiscence was noted in total of 2 patients out of which 1 was male and 1 was female. Partial flap necrosis with dehiscence was seen in only 1 male patient. No such complication was seen in females. There was no case of total flap necrosis in the study.

Conclusion: Ulnar artery perforator flap is a reliable flap for coverage of soft tissue defects over wrist and distal forearm region. Ulnar artery perforators are quite consistent in their location.

Keywords: Ulnar artery perforator flap, soft tissue defects, flap survival

INTRODUCTION

Electric injuries of wrist are a difficult reconstructive challenge for plastic surgeons, especially when tendons, nerves, or bones are exposed. These electric injuries necessitate immediate flap coverage¹ to preserve vital structures and hand function. These injuries are very common in our country and is a cause of major morbidity. The burn of electric injury is usually very deep and one or both of the arteries of hand are injured at the wrist along with nerves and tendons. In these cases vascularized flap coverage is required immediately after thorough debridement. Pedicle groin flap or abdominal for the resurfacing of wrist and distal forearm are considered options especially in cases where the deeper structures like bone or tendon are exposed or involved. These flaps give reliable and stable cover but have disadvantage of two stage procedure and post-operative position is difficult to maintain. Moreover, the hand in this position can leads to oedema and joint stiffness. So two-stage distant pedicle flap procedures are avoided when single stage options are available. In many situations, reconstruction with distal free tissue transfer is required for hand defects. However, free tissue transfer requires great expertise and a dedicated setup and team. Electric injuries are usually associated with vascular compromise. Doing

microvascular anastomosis in such cases become highly unreliable and difficult to perform and may need long interposition vein grafts. This may require additional donor site for harvesting a vein graft^{2,3}.

Local and regional tissue of upper limb is always preferred over distant tissue as it will provide same sensibility and has better tissue match⁴. Regional flaps are used if the local flaps are insufficient to meet the requirements of reconstruction. Single stage procedure which can give well vascularised tissue coverage at the earliest possible time offers best possible functional outcome by reduction in fibrosis, scarring and hospital stay⁵.

Reverse radial forearm flap has become a workhorse locoregional flap for soft tissue reconstruction of hand, wrist and forearm defects⁶. This flap has advantage of long length of pedicle; arc of rotation and can provide reliable one stage coverage. Its disadvantage is that one of the major source blood vessels of the distal forearm and hand is compromised. This result in reduced perfusion of hand and may cause claudication. Other major disadvantage is poor aesthetic outcome of the donor site that has to be skin grafted in a more conspicuous area. Another major short coming is that in electric injuries radial or ulnar arteries are usually damaged and reverse radial forearm flap can't be done in these situations. Ulnar artery based flap has never gained much popularity due to the concern of ulnar artery dominance. Moreover, there is risk of damage to ulnar nerve⁷⁻¹⁷. Traditional ulnar artery forearm flap is

Jinnah Burn & Reconstructive Surgery Center, Jinnah Hospital, Allama Iqbal Medical College, Lahore
Correspondence to Dr. Kamran Khalid, Email: drkamrankhalid@hotmail.com

harvested similar to that of the radial forearm flap, and it also has similar limitations.

The disadvantage of vessel sacrifice in radial and ulnar artery based flap can be overcome by use of pedicled perforator flap on ulnar artery¹⁷. Moreover; the skin on ulnar side of forearm is usually hairless. Peirongyu et al¹⁸ described perforator pattern of ulnar artery. He found three cutaneous perforators consistently and directly arising from ulnar artery. Based on these perforators ulnar artery perforator flap can be harvested. The dimensions and arc of rotation of ulnar artery perforator flap makes it a very good option for coverage of distal forearm and wrist wounds. In our study, we provided soft tissue coverage to suitable patients with soft tissue defects on wrist. We based flap on one of these perforators of ulnar artery.

We found that this flap has advantages of single stage procedure, reliable vascularity, easy flap dissection, no sacrifice of major vessel and it can be done even in situations where one of the vessels is already damaged.

MATERIALS AND METHODS

This descriptive study was conducted at Plastic Surgery Department Jinnah Hospital, Lahore, from October, 2013 to August, 2015. All male and female patients between 5 -65 years of age, having post electric injury wounds or unstable scar exclusively on volar surface of wrist were included in this study. The patients with damaged proximal ulnar artery or having peripheral vascular disease were excluded from the study. Also patients having extensive electric injury defects including palm or forearm along with wrist were excluded from the study. Doppler was performed in all patients preoperatively to select best available perforator and to design flap. First incision was given on the radial margin of proposed flap. The flap was raised in subfascial plane from radial to ulnar side and perforators were identified supplying the skin. After identification of perforators, incision was completed on ulnar side. The best perforator for the flap according to arc of rotation was chosen and others were temporary clamped. On releasing tourniquet and after confirming perfusion of flap the clamped perforators were ligated. Further gain in length in perforator if required, was achieved by further dissecting the perforator up to the parent artery. Donor site was either closed primarily or with split thickness skin grafting. Post operatively sling for hand elevation was advised for 3-4 days to reduce oedema. First dressing was opened on 4th postoperative day. If uneventful, patient was discharged and was followed on weekly basis for 3 weeks. Outcome variable were being taken as flap

success and data was recorded. Outcome of patient was assessed in terms of Flap success (if covering flap survives without necrosis) (Figs.1-4). Complications were taken as; partial necrosis without dehiscence, partial necrosis with dehiscence and total necrosis.

Fig. 1: Right handed adult patient with high voltage electric current injury left wrist

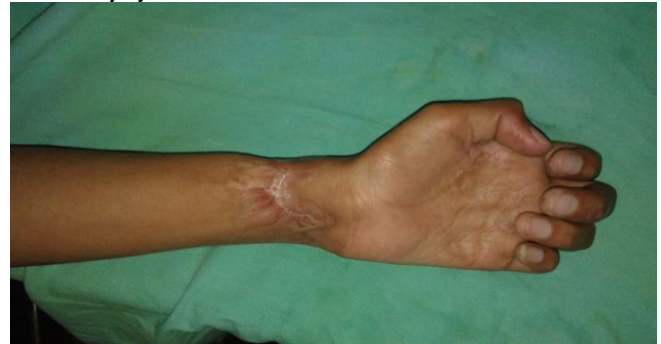

Fig. 2: Perforator identification

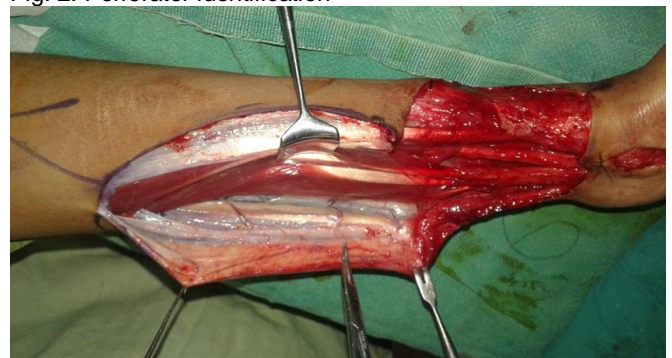


Fig. 3: Flap raising and rotation

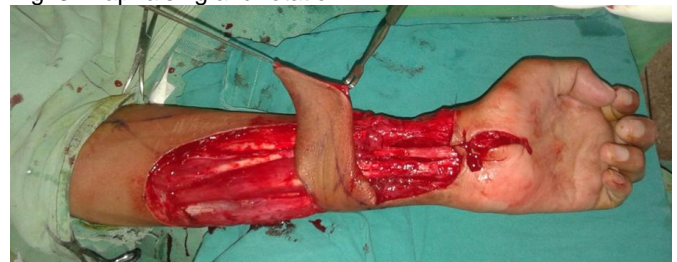
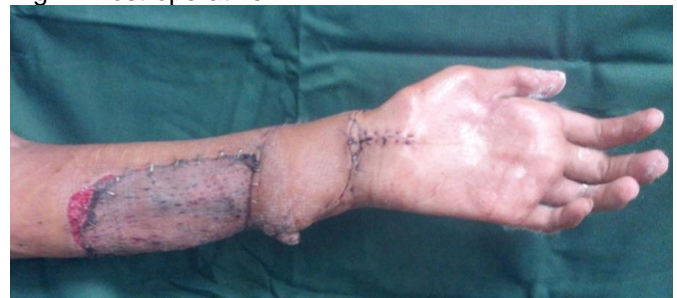
Fig. 4: Post-operative



RESULTS

We enrolled total 19 patients out of which 15(79%) were male and 4(21 %) were female with soft tissue defects or unstable scar over the wrist. Partial flap necrosis without dehiscence was noted in total of 2 patients out of which 1 was male and 1 was female. Partial flap necrosis with dehiscence was seen in only 1 male patient. There was no case of total flap necrosis in the study (Table 3). Ulnar artery perforator flap can cover a large size of defects. In this study the largest size being 102 cm² and the minimum was 25 cm². The mean wound size was 42.68cm². Most of the patients have 3 perforators with total of 14(73.5%) patients having 3 perforators (Table 2). Most consistently found perforator was at the distance of 11±1 cm from the pisiform bone that was present in 17(89.5%) cases. 15(79%) cases had perforators at 7±1 cm and 16(84%) patients had perforators at 15±1cm from pisiform bone (Table 3).

Table 1: Number of perforators found preoperatively (n=19)

Perforators	n	%age
Single	-	-
Two	3	16.0
Three	14	73.5
Four or more	2	10.5

Table 2: Common site of perforators (n=19)

Distance from pisiform (cm)	n	%age
7±1	15	79.0
11±1	17	89.5
15±1	16	84.0

Table 3: Flap survival on follow up visit at 3rd week (n=19)

Flap survival	n	%age
Complete survival	16	84.5
Partial necrosis without dehiscence	2	10.5
Partial necrosis with wound dehiscence	1	5.0
Complete necrosis	-	-

DISCUSSION

Post electric injury wrist wound reconstruction either small or large is always a challenge for plastic surgeons. Soft tissue coverage and good functional outcome are the primary concerns. The soft tissue loss is mostly accompanied by injury to underlying vessels, nerves, tendons and bones. Soft and pliable tissue is mandatory for better outcome and early joint mobility. Ulnar artery flap has never gained much of popularity as compared to the radial forearm flap because of its tedious dissection in harvest. There are also apprehensions about "ulnar dominance" in hand perfusion^{19,20}. This fact is overwhelmed by use of perforator based flap that doesn't sacrifice any

major vessel. So assessment of Allen test for dominant vessel may be limited²¹.

Electric injury burns are usually very deep and one or both of the arteries of hand is injured at the wrist along with nerves and tendons. Ulnar artery perforator does not sacrifice any major vessel of forearm and it can be done even in situations where one of the vessels is already damaged. In our study we found, the greater and constant perforators are located at 3 areas: 7±1cm, 11±1cm and 15±1cm proximal to the pisiform bone on a line drawn between pisiform to medial epicondyle. These perforators facilitate surgeons with multiple options for any given paddle of skin in this area. This flap has two distinct advantages i.e. it saves the ulnar artery and allows arterial and venous flow in physiologic directions. The maximum size possible for ulnar artery perforator flap survival is yet to be described. However, the maximum size of flap we harvested in our series was 17.0×6.0cm.

As compared to any local pedicled flap, the ulnar artery perforator flap has several advantages, like preservation of major vessel, more inconspicuous scar location, lesser donor site complications²². We found that if flap is harvested in width more than 5 cm, the donor site need split thickness skin graft for wound coverage. So we can conclude that ulnar artery perforator flap is one best option for small to medium size skin defects of wrist.

Yu¹⁸ studied the size of ulnar artery perforators, their number and location intraoperatively for head and neck reconstruction as free flaps. He designated 3 cutaneous perforators from distal to proximal as A, B and C. 79% of cases had perforator A that was located 7.3±1.1cm proximal from the pisiform. B Perforator in 95% of cases and was present at 11.4±1.0 cm from the pisiform proximally. 87% cases had perforator C that was located 15.9±1.8cm from the pisiform. He observed that all patients had minimum of two perforators. Only 61% case had 3 consistent perforators. There was no case of flap failure and they labelled as success of flap. He observed minimal donor site morbidity. There was a transient decrease of grip strength postoperatively. All of the patients recovered completely to the level as that of contralateral side by 3 months. He concluded that there are at least 2 consistent perforators in all the cases and is a reliable flap with minimal donor site morbidity. Also suggested that this flap can be used as an alternative to the radial forearm flap. This study finding is very much compatible with our study results not only in terms of flap survival but also in terms of location of perforators.

CONCLUSION

Ulnar Artery perforator flap is an ideal option for soft tissue reconstruction of wrist. It can be used in acute or late cases with high or low voltage electric injuries involving the distal forearm and wrist. It has a reliable perforator location with 11 cm perforator being the most dominant. Flaps as big as 6cm x 17cm can be raised on a single ulnar artery perforator. Donor site morbidity is less than radial artery forearm flap and soft tissue reconstruction is far superior to a skin graft. All of this without sacrifice of a major artery of the forearm.

REFERENCES

1. Becker C, Gilbert A. Le lambeau cubital: the ulnar flap. *Ann Chir Main* 1988;7:136-42.
2. Koog T. Electrical injuries. *J Trauma* 1970; 10:816-30.
3. Solem L, Fischer RP, Strate RG. The natural history of electrical injury. *J Trauma* 1997; 17:487-92.
4. Sieg P, Bierwolf S. Ulnarverses radial forearm flap in head and neck reconstruction. an experimental and clinical study. *Head Neck*, 2001; 23:967-71.
5. Dogra BBB, Singh M, Chakravarty B, Basu S. Posterior interosseous artery flap for hand defects. *MJAFI* 2006; 61(1): 33-5.
6. Biemer L.. The forearm radial arterial turnover flap and its clinical applications. *Eplasty* 2009;10:491-7.
7. Graf P, Biemer E. Morbidity of the groin flap transfer, are we getting something for nothing?' *Br J Plast Surg* 1992; 45: 86.
8. Haerle M, Haefner HM, Dietz K, Schaller HE, Brunelli F. Vascular dominance in the forearm. *Plast Reconstr Surg* 2003; 111: 1891-8.
9. Hansen TB, Carstensen O. Hand injuries in agricultural accidents. *J Hand Surg* 1999;24: 190-92.
10. Harvey KD, Barillo DJ, Hobbs CL, Mozingo DW, Fitzpatrick JC, Cioffi WG, et al. Computer-assisted evaluation of hand and arm function after thermal injury. *J Burn Care Rehab* 1996;17: 176-80.
11. Helm PA. Burn rehabilitation: dimensions of the problem. *Clin Plast Surg* 1992; 19: 551-9.
12. Hill C, Riaz M, Mozzam A, et al. A regional audit of hand and wrist injuries. *J Hand Surg (Br)* 1998; 23:196-200.
13. Hung LK, Choi KY, Yip K, et al. Recent changes in the pattern of hand injuries in Hong Kong: a regional hospital survey. *Hong Kong Med J* 1997; 3:141-8.
14. Jaimie T, Shores WP, Lee A. 'Management of mutilating injuries of the upper extremity. In: Throne CH, Chung KC, Gosain AK, Gurtner GC, Mehrara BJ, eds. *Grabb and Smith's Plastic Surgery*. Philadelphia: Wolters Kluwer - Lippincott Williams & Wilkins, 2014; pp. 833.
15. Javaid M, Cormack GC. Anterolateral thigh free flap for complex soft tissue hand reconstructions. *J Hand Surg* 2003; 28 (B): 21.
16. Jawad AS, Harrison DH. The island sensate ulnar artery flap for reconstruction around the elbow. *Br J Plast Surg* 1990; 43: 695-8.
17. Jihui JU, Liu Y, Hou R. Ulnar artery distal cutaneous descending branch as free flap in hand reconstruction. *Injury* 2009;40: 1320-26.
18. Yu P, Chang EI., Selber JC, Hanasono MM. Perforator patterns of the ulnar artery perforator flap. *Plast Reconstr Surg* 2012; 129:213-20
19. Coleman SS, Anson BJ. Arterial patterns in the hand based upon a study of 650 specimens. *J Surg Gynecol Obst* 1961;115: 409-24.
20. Doscher W, Viswanathan B, Stein T, Margolis IB. Hemodynamic assessment of the circulation in 200 normal hands. *Ann Surg* 1983;198: 776-9.
21. Khan AS, Henton JM, Adams TS, Dwivedi RC, Harris PA. Evaluation of hand circulation before radial forearm free flap surgery. *Laryngoscope* 2009; 119: 1679-81.
22. Yu P, Chang EI, Selber JC, et al. Perforator patterns of the ulnar artery perforator flap. *Plastic Reconstr Surg* 2001;129, 213-20.